Retinal Haemorrhage at Altitude

JOHN R. SUTTON, M.B., B.S., M.R.A.C.P., F.R.C.P.(C)*, GARY W. GRAY, M.D., Ph.D., MURRAY MCFADDEN, M.D., A.C. PETER POWLES, M.B., B.S., F.R.A.C.P., F.R.C.P.(C) *and* CHARLES S. HOUSTON, M.D.

ON MOUNT LOGAN, Canada's highest mountain, retinal haemorrhage was first noticed by Dr. Charles Houston in 1968. A member of the support party, climbing Mount Logan from the Trench camp at 10,000 feet, became exhausted on the way up and after arrival at 17,500 feet was irrational and unable to care for himself. He was put in a tent and kept warm, but bad weather conditions prevented his evacuation. After some 30 hours at the high camp, he was flown off the mountain to Whitehorse Hospital where he was found to have small haemorrhages in the retinae of both eyes. In retrospect, he was also thought to have had cerebral oedema. This was one of the first observations of retinal haemorrhage at altitude and was followed by a more detailed study conducted by the HAPS** group, which led to the publication of a paper "Retinal haemorrhage at high altitude," published in *The New England Journal of Medicine* in 1970. In that particular study, 9 out of 25 individuals taken to 17,500 feet were found to have retinal haemorrhages. Dr. Drummond Rennie and several others have subsequently noted retinal haemorrhages in Himalayan climbers.

These intriguing observations led to more detailed studies using a retinal camera for retinal photography. In addition, the use of fluorescein enabled detection of "leaky" blood vessels, because fluorescein extravasates outside any damaged blood vessels in the eye. Other equipment enabled us to plot visual fields with a precision which detects small blind spots

---

* Correspondence: Dr. J.R. Sutton, Room 3U26, McMaster University Medical Centre, 1200 Main Street, West, Hamilton, Ontario, Canada L8S 3J9.

** HAPS—High Altitude Physiological Studies.

PLATE 73

Photo by J.R. Sutton

Examining for Retinal Haemorrhage on Mount Logan.

that would normally not be noticeable to an individual. These latter studies have been under the direction of Dr. Murray McFadden.

What, then, is the nature of these retinal haemorrhages? How do they occur? Are certain individuals more susceptible than others and can they be identified at sea level? What is the altitude at which retinal haemorrhages occur and is there a minimum time required at altitude? Are there any precipitating factors which could, perhaps, be avoided? What is the clinical significance of retinal haemorrhages and how should they be treated? Do they leave permanent scars? Should the "victim" descend at once? May he climb again?

All of these are questions to which we in the Mount Logan group have addressed ourselves over the last few years and most important, of course, what are the clinical implications of retinal haemorrhages at altitude? Should a person, if he or she develops retinal haemorrhage, be immediately evacuated off the mountain, as some authors imply, or can it be ignored? Although we do not have answers for all of these questions, parts of the jigsaw are now starting to fit into place.

Altitude of Occurrence

There does appear to be a minimum altitude required before retinal haemorrhage occurs. In our experience on Mount Logan, no haemorrhages have occurred at the lower staging camp, which has now been used for five years, at approximately 10,000 feet. Furthermore, in a short-term study in an altitude chamber at 14,500 feet, no retinal haemorrhages were found over a period of 24 hours, even with maximal exertion. However, at 14,000 feet on Mount McKinley a very few retinal haemorrhages have been noted. At an altitude of 17,500 feet on Mount Logan, over the years the incidence has ranged from 30% to 60%. (This incidence comes from examining retinal photographs which reveal far more haemorrhages than does simply looking at the fundus.)

Predisposed Individuals

So far, it has been impossible to predict which subjects will develop retinal haemorrhages and it is of further interest that there appears to be little correlation with other features of mountain illness, such as acute mountain sickness or high altitude pulmonary oedema. These haemorrhages can occur in people who are completely asymptomatic and have had no evidence of acute mountain sickness. On the other hand, people with severe acute mountain sickness—cerebral oedema and pulmonary oedema—will almost always have retinal haemorrhages.

Precipitating Factors—Physical Exercise

One of the current thoughts is that severe exercise such as climbing or straining, e.g., at stool when constipated, may produce two effects that

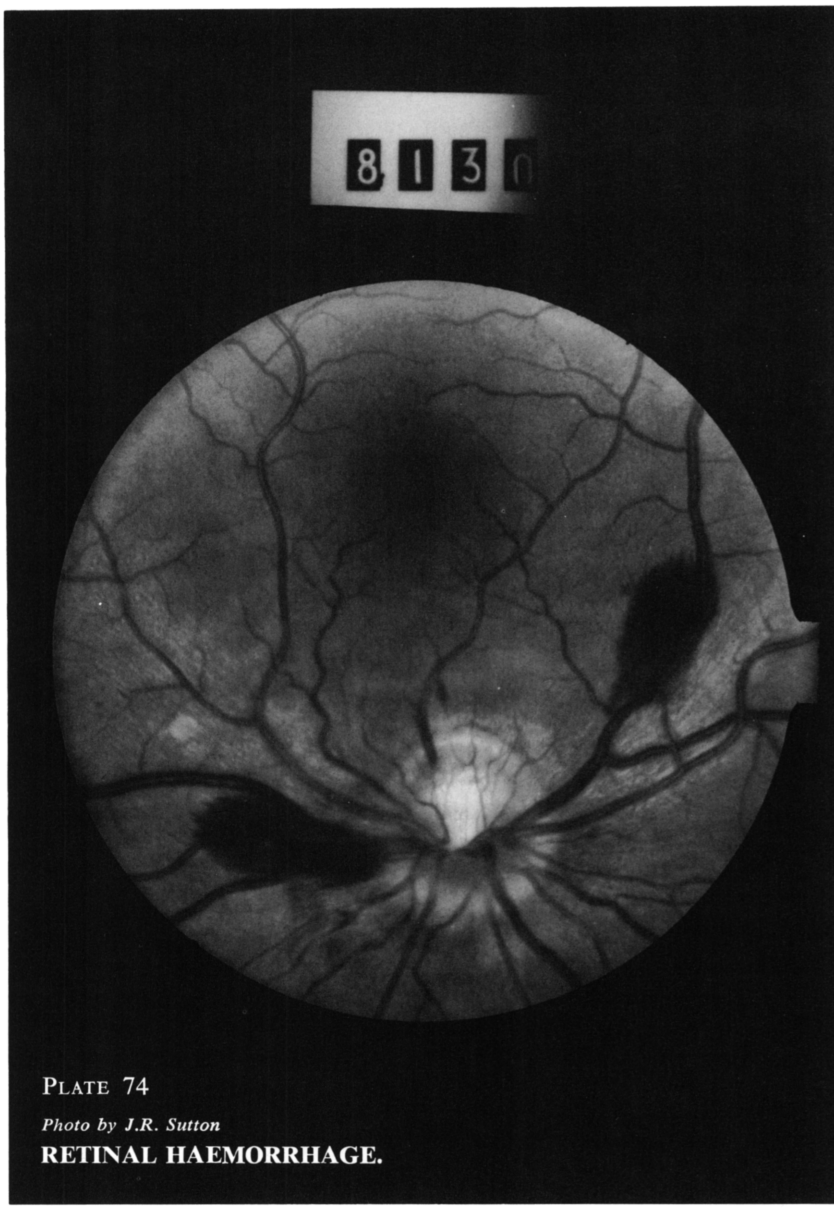

PLATE 74

Photo by J.R. Sutton

RETINAL HAEMORRHAGE.

could conceivably precipitate retinal haemorrhage. The first is the elevation of systolic arterial blood pressure which occurs during any form of exercise, whether it be static or dynamic, and the second is the performance of the Valsalva manoeuvre, such as when straining at stool. This elevates both the arterial and the venous pressure. At altitude, the retinal blood flow more than doubles in everyone and the blood vessels are dilated. One hypothesis is that under these circumstances, an elevation in arterial pressure and/or an elevation in venous pressure can predispose the already maximally dilated blood vessels to an extra strain which may cause fluid leakage and frank haemorrhage.

Clinical Significance

Two examples of high altitude retinal haemorrhage will be presented to illustrate the significance of retinal haemorrhage. The first, a 26-year-old female mountaineer, developed multiple bilateral peripheral retinal haemorrhages during a climb of Mount McKinley. These were noted a week after descent, during baseline studies for the Mount Logan project. On Mount Logan, not only did no fresh haemorrhages occur, but there was resolution of the previous haemorrhages while at 17,500 feet. At no time was she aware of any visual abnormalities.

The second example is that of one of the Mount Logan scientists, who bumped into a post and discovered his visual abnormality. He was found to have a haemorrhage in the area of the macula (the area of the retina with most visual discrimination) and was flown off the mountain. His vision has since returned to normal.

The significance of retinal haemorrhages depends on their location, whether they are peripheral or central. Peripheral haemorrhages, as in the female mountaineer, generally lead to no visual abnormality obvious to the owner. They do not usually affect vision and, therefore, should not impair climbing ability. Central haemorrhages in the region of the macula, as in the scientist, interfere with visual discrimination leading to difficulties in seeing detail and also in depth perception. Bilateral macular haemorrhages would be serious and could render a person incapable of climbing—so far, we have not seen such a case.

The long-term significance of retinal haemorrhage at altitude and its effect on vision is unknown. However, we (the HAPS group) have commenced detailed long-term followup studies of vision in subjects found to have retinal haemorrhage at altitude. At present, it would appear that few, if any, have persistent visual disturbance as a result of high altitude retinal haemorrhage. An important exception is the haemorrhages which occur in the central (macular) region: a visual defect may persist in such individuals for several years or even longer. Macular haemorrhages must be taken seriously. A similar lack of long-term visual defects is found in newborn infants, 35% of whom have retinal haemorrhage at birth.

Management

What should one do if a climber is found to have a retinal haemorrhage? The following approach comes from our experience with more than 50 cases of high altitude retinal haemorrhages and is based on the following classifications; it represents the present opinion of the HAPS group:

1. Asymptomatic retinal haemorrhage, but otherwise well—no specific treatment and no restriction of activity.
2. Asymptomatic retinal haemorrhage with acute mountain sickness or pulmonary oedema—treatment of the acute mountain sickness or pulmonary oedema. Therefore, evacuation, if necessary.
3. Symptomatic retinal haemorrhage, i.e. visual defect. If an objective abnormality of the visual fields is present or if the haemorrhage is in the macular area of the retina, then evacuation is advisable. (N.B. It is important to know whether such a defect in vision was present before the ascent.)

Using this approach, we have evacuated two persons (both scientists) solely because of retinal haemorrhage and we have not curtailed the activity of any other members who had haemorrhages.

Summary

Retinal haemorrhage is common at high altitude, but will normally go unnoticed, as most do not cause obvious visual problems. There appears to be a critical altitude above which retinal haemorrhages occur and they may be provoked by exercise. They resolve spontaneously even at altitude. If asymptomatic (no visual disturbance and otherwise well), climbing activity need not be modified. However, should there be a visual defect or macular haemorrhage noted with an ophthalmoscope, descent would be wise.

Acknowledgements

The Mount Logan High Altitude Physiology Studies (HAPS) group is multinational. It is conducted under the auspices of the Arctic Institute of North America. It is logistically supported by the Canadian Armed Forces and funded by the National Institutes of Health and the United States Army. The project leader is Dr. Charles Houston (K2). Scientists specifically involved in the retinal haemorrhage studies, past and present, include Dr. Regina Frayser, Dr. Drummond Rennie, Dr. Murray McFadden, Dr. David Arnold and Dr. Gary Gray.